

# Cavernous malformation of left basal ganglia region in a 12-year-old boy - case report.

Marek Mandera<sup>(1)</sup>, Mikołaj Zimny<sup>(2)</sup>, Anna Karolina Malec<sup>(2)</sup>, Daniel Bula<sup>(2)</sup>, Michał Bałuszyński<sup>(2)</sup>

<sup>1</sup> Department of Emergency Medicine and Pediatric Neurosurgery, School of Public Health, Medical University of Silesia in Katowice

<sup>2</sup> Department of Emergency Medicine and Pediatric Neurosurgery, School of Public Health, Student Scientific Association, Medical University of Silesia in Katowice

Received – 4 July 2017; Accepted – 12 July 2017

## A B S T R A C T

**Intro:** Cerebral cavernous malformations are benign lesions composed of abnormally stretched-out, thin-walled blood vessels clustered together and filled with blood. This paper reports a case of cerebral cavernous malformation located in the left subcortical nuclei region with additional venous angioma, and reviews the literature.

**Case presentation:** The 12-year-old boy presented with progressive right-sided spastic paresis which occurred at the age of five. First diagnostic procedures were performed after the first appearance of the neurological symptoms. The patient was diagnosed with cavernoma. Due to progression of the right hemiparesis he was admitted to the hospital for a surgical treatment. The patient underwent a left frontotemporal craniotomy. The cavernous angioma was excised and sent for histopathological examination which confirmed the diagnosis of the cavernous angioma. The early postoperative period was complicated with right sided paresis and signs of motoric aphasia. In a few days after surgery symptoms started to withdraw except for the deep paresis of right upper limb and central paresis of the right facial nerve which turned out to be temporary. We should underline, that remaining symptoms originated not only from operation, but also occurred as a result of underlying disease.

**Discussion:** Cerebral cavernous malformations located in the subcortical region are particularly difficult and risky to resect. Even careful planning and interdisciplinary approach cannot promise full recovery. Additionally, children post-operative care should always contain psychological care. This can help patients and their families overcome fear associated with disease and its treatment resulting in faster recovery.

**Key words:** cavernous malformation, DVA, children, surgery

**Corresponding author:** Mikołaj Zimny - zimny.mikolaj@gmail.com

## INTRODUCTION

Cerebral cavernous malformations (CCM) are benign lesions composed of abnormally stretched-out, thin-walled blood vessels clustered together and filled with blood. CCMs are usually located in the brain but may be found in any of the CNS locations as well. They may vary in size from less than 5 mm up to 10 cm. Due to lack of the tissue within the malformation and non-encapsulated borders, CCMs can grow over time. Depending on location, size and hemorrhage occurrence the lesions may be asymptomatic or cause a wide variety of stroke-like symptoms and seizures.<sup>1,2</sup> In pediatric series, CCMs represent 1.7%–18% of all vascular growths.<sup>3,4</sup> CCMs are estimated to develop in approximately 0.2% of the general population and are usually present from childhood.<sup>5</sup> CCMs may be hereditary (caused by mutations in the MAP3K3 genes) leading to occurrence of familial form inherited in an autosomal dominant manner with multiple cavernous angiomas.<sup>2</sup> Almost half of the CCMs tumors occur in the proximity of venous angioma, which when damaged during surgery, may lead to cerebral venous infarction.

The authors present a boy with a CCM tumor located in the left subcortical nuclei region with additional venous angioma, causing progressive right-sided spastic paresis, and present a review of the literature regarding diagnosis and treatment for this lesion.

## CASE PRESENTATION HISTORY AND EXAMINATION

The 12-year-old boy presented with progressive right-sided spastic paresis which occurred at the age of five. He also had congenital talipes equinovarus and limb-kinetic apraxia involving right limbs. Patient did not present seizures of any kind. In 2002 patient underwent surgical open reduction and internal fixation (ORIF) of right femoral bone due to fracture. In 2011 patient had percutaneous Achilles tendon lengthening on the right side. His family history was not contributory.

First diagnostic procedures (EEG, CT, MRI) were performed in 2006 after the first appearance of the neurological symptoms. The patient was diagnosed then with cavernoma. In 2009 also fMRI was performed but because of location of lesion, patient was left under observation only. Control MRI of the patient's head (figure 1), performed after admission to the hospital, showed well-defined left cerebral lesion measuring 20 mm with grainy signal enhancement in T2 and surrounded by a low-signal intensity zone (due to hemosiderin deposit). This scan revealed the volume increase of the lesion but with no signs of bleeding and confirmed its location in the left subcortical area, near posterior parts of the internal capsule and lentiform nucleus.

## SURGERY

The patient underwent a left frontotemporal craniotomy. After exposing the lateral fissure of the brain, the left lateral fissure was opened and the surface of the insula was revealed. Using the intra-operative image guidance, the incision of the insula (15 mm) was made and 10 mm under the surface of this brain area the CCM was found. The lesion (diameter 20 mm in diameter) was gradually separated and removed. During this procedure small bleeding from the vessel accompanying the CCM occurred, but it was stopped successfully using bipolar coagulation. The cavernous angioma was excised (according to surgeon evaluation) and sent for histopathological examination. After resection, the cavity was thoroughly inspected for hemostasis and residual lesion. The bone flap was replaced and the muscles and skin were sutured back together. Histopathology examination confirmed the diagnosis of the cavernous angioma.

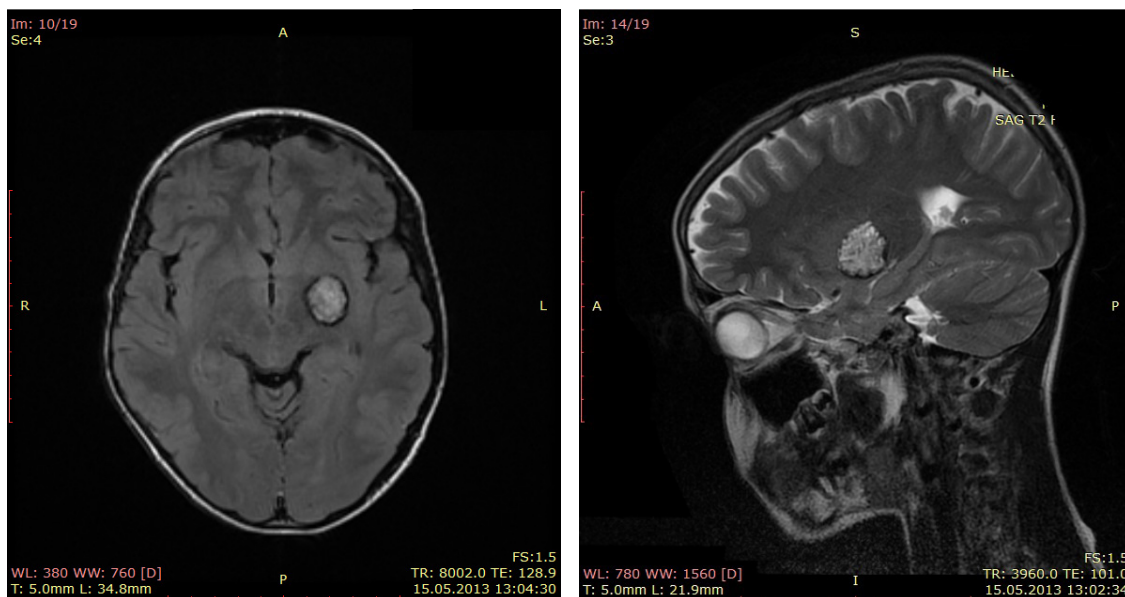


figure 1  
Preoperative axial MRI image (left) and preoperative sagittal MRI image (right)

Patient in neurological exam presented gradually increasing symptoms of right-sided paresis with disorders in precision movement in upper right limb. Due to progression of the right hemiparesis he was admitted to the hospital for a surgical treatment.

## FOLLOW-UP

The early postoperative period was complicated with right-sided paresis and signs of motoric aphasia. Postoperative CT scan (figure 2) showed tumour bed after resected lesion. In a few days after surgery symptoms started to withdraw except for the deep paresis of right upper limb (4 points in Lovett scale) and central paresis of the right facial nerve. The latest MRI revealed, that small amount of tumor tissue was left. During final follow-up patient was stable and in logical contact. In the physical examination, knee

reflexes were stronger on the right side and an increased tension of wrist flexors had been noticed. Surgical wound healed correctly. Fortunately, paresis of the facial was no longer present. Because of the increased tension in the right wrist flexors patient was qualified to botulinum injection therapy, but because of the lack of consent for a pharmacological analgosedation patient was discharged home. Patient's mother stated that he had a tendency to depression states after prescribed drugs (piracetam), and because of that patient have been no longer taking them. We should underline, that remaining symptoms originated not only from operation, but also occurred as a result of underlying disease.

represent a risk factor for posttraumatic hemorrhage. In such cases surgical treatment should be considered.<sup>7</sup>

Counseling pediatric patients and their parents can be very challenging thus extensive data regarding subcortical CCMs is needed. This is of great importance while planning elective procedures, such as the resection of a lesion, consequently the "wait-and-see" strategy may be rejected. A detailed and multidisciplinary approach is proven to maximize potential postoperative patient outcome.<sup>8</sup> Patients with non-progressing but affecting the quality of life symptoms may benefit from carefully planned surgery. It had been shown in adult population that almost all

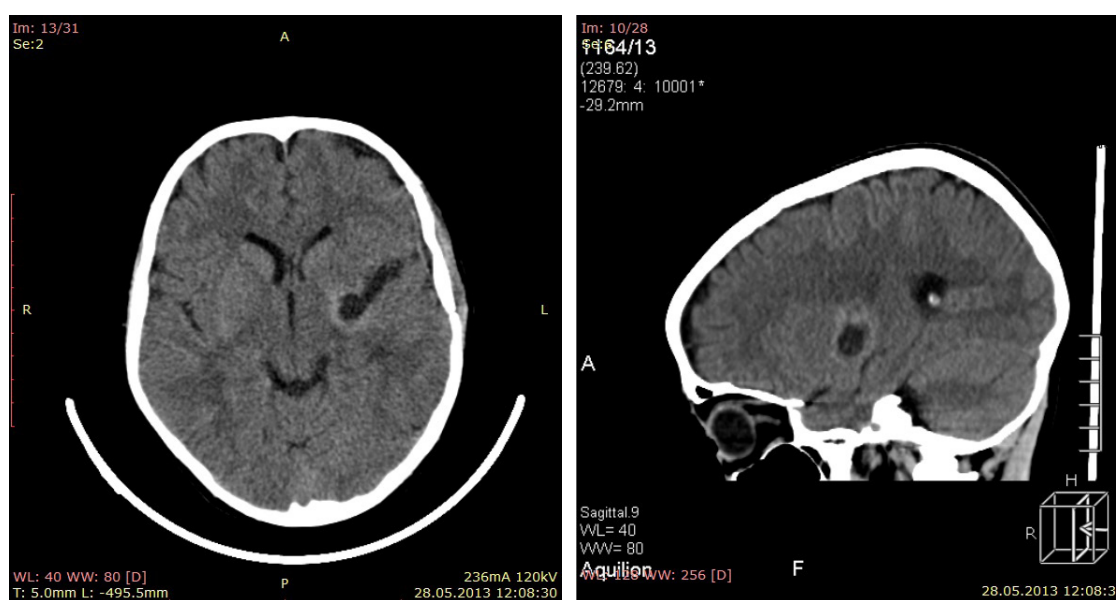


figure 2  
Postoperative axial CT image (left) and postoperative sagittal CT image (right)

## DISCUSSION

We find this case to be interesting, due to relatively rare location of lesion in the pediatric patient. Although CCMs have been reported in infants and children, the majority become evident between the second and fifth decades with symptoms such as seizures, focal neurologic deficits, nonspecific headaches, and cerebral hemorrhage.<sup>1,2</sup> Cavernomas are uncommon vascular malformations,<sup>5</sup> usually supratentorial and superficial in location. CCMs located in subcortical or insular lobe area represent a unique challenge for neurosurgeons to safely access and resect the lesion. Relatively few cases with similar location had been reported in the world literature so far and only few authors provide clear recommendations whether CCMs in the critical regions of the brain should be operated.<sup>6</sup> In case of our patient, the clinical symptoms manifested because of the progressive increase in volume of the lesion and the operation had to be performed. Additionally patient's young age predispose to more frequent trauma occurrence, which with associated venous angioma may

patients who experience a first seizure associated with a CCM, will develop epilepsy in a 5-year follow-up period<sup>9</sup> but seizures are not the only symptoms that may progress over time. Studies performed on larger groups of CCM patients<sup>10,11</sup> argue for an earlier surgery in pediatric patients suffering from CCM. Even with more extensive surgical approach, the longer symptoms are present, the worse treatment outcomes become. Surgery for CCMs in the pediatric population is safe but there is a relevant rate of permanent anticipated deficits reported in the literature.<sup>10</sup> In some cases, when lesions cannot be treated surgically, radiotherapy may be used. In our case CCM was removed completely using transylvian transinsular approach, however other approaches can be used as well. Multimodal work-up diagnostics enable neurosurgeons to individually customize access and the extent of resection.

CCMs located in the subcortical region are particularly difficult and risky to resect. As we can see from follow-up results, even careful planning and interdisciplinary

approach cannot promise full recovery. We need to remember that patient was qualified for a surgery, not only because of his young age but mostly because of his gradually deteriorating quality of life. Another conclusion is that in children post-operative care should always contain psychological care. This can help patients and their families overcome fear associated with disease and its treatment. Additionally, it may help follow doctors' instructions resulting in faster recovery.

## REFERENCES

1. Ellis JA, Barrow DL. Supratentorial cavernous malformations. *Handbook of Clinical Neurology*, 2017;143:283-289
2. Morrison L, Akers A. Cerebral Cavernous Malformation, Familial. *GeneReviews* [internet], 2014
3. Lee JW, Kim DS, Shim KW, Chang JH, Huh SK, et al. Management of intracranial cavernous malformation in pediatric patients. *Childs Nervous System*, 2008;24:321-327
4. Lim SC, Hong R, Kim YS, Jang SJ. Large cystic cavernous angioma of the cerebellum mimicking pilocytic astrocytoma. *Journal of Neuro-Oncology*, 2006;79:169-170
5. Kumar V, Nair R, Kongwad L, Menon R G. Cavernous hemangioma of the cauda region: case report and review of literature. *British Journal of Neurosurgery*, 2016;22:1-2
6. Roberto P, Leal L, Houtteville JP, Etard O, Emery E. Surgical strategy for insular cavernomas. *Acta Neurochirurgica*, 2010;152:1653-1659
7. Fanous AA, Jowdy PK, Lipinski LJ, Balos LL, Li V. Association between trauma and acute hemorrhage of cavernous malformations in children: report of 3 cases. *Journal of Neurosurgery: Pediatrics*, 2016;18(3):263-268
8. Clusmann H. Predictors, procedures, and perspective for temporal lobe epilepsy surgery. *Seminars Ultrasound, CT, and MRI*, 2008;29:60-70
9. Josephson CB, Leach JP, Duncan R, Roberts RC, Counsell CE et al. Seizure risk from cavernous or arteriovenous malformations: prospective population-based study. *Neurology*, 2011;76:1548-1554
10. von der Brelie C, Kuczaty S, von Lehe M. Surgical management and long-term outcome of pediatric patients with different subtypes of epilepsy associated with cerebral cavernous malformations: Clinical article. *Journal of Neurosurgery: Pediatrics*. 2014;13:699-705
11. Hugelshofer M, Acciarri N, Sure U, Georgiadis D, Baumgartner RW et al. Effective surgical treatment of cerebral cavernous malformations: a multicenter study of 79 pediatric patients. *Journal of Neurosurgery: Pediatrics*. 2011;8:522-525